


Acute ankle injuries are a common problem seen by physiotherapists and sports physicians, particularly in health and fitness programmes where rapid changes of direction are required.

ANKLE SPRAIN

COMMON INJURY

The most important aspect of managing injury in the ankle region is ensuring a correct diagnosis – the key issue is deciding on whether the injury involves damage to the ankle ligaments only, or a more complex injury involving possible fractures or tendon dislocations.



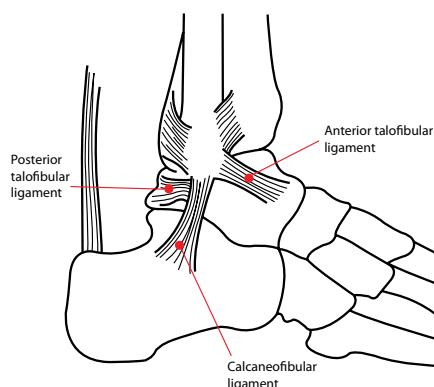


Anatomy and physiology

The ankle consists of three joints:

1. talocrural joint (ankle joint) – a hinge joint between the bottom of the tibia and the top of the talus
2. inferior tibiofibular joint – this is the joint between the distal parts of the tibia and fibula
3. subtalar joint – this is the joint between the talus and the calcaneus (heel bone)

The ligaments of the ankle are shown on the diagram below. There are three major ligaments on the lateral side of the ankle – these are the anterior talofibular ligament (often written as ATFL), the calcaneofibular ligament (CFL) and the posterior talofibular ligament (PTFL).



The medial side of the ankle is supported by the strong, fan shaped medial or deltoid ligament – which runs from the medial malleolus down to the navicular, talus and calcaneus.

Mechanism of injury and diagnosis

Due to the relative weakness of the lateral ligaments and the instability of the lateral side of the ankle, it is much more common to sustain an inversion injury (where you roll on to the outside of the ankle) than an eversion injury (where you roll on to the inside of the ankle).

The abovementioned mechanism of injury (inversion or eversion) will aid in the provisional diagnosis of a lateral or medial ligament injury – it is important to be aware that if compression forces are involved (ie, landing from a jump shot in basketball) then a bony injury, such as an osteochondral fracture to the dome of the talus, may be more likely due to the rotational forces that are magnified in higher impact injuries.

Other important clues that can assist in accurate diagnosis and treatment plan are the location of pain, the ability to bear weight after the injury, and the extent of pain and swelling. Ankle sprains can be accompanied by an audible snap or crack which may actually have no clinical significance and give no extra clues to the extent of the injury.



It is much more common to sustain an inversion injury (where you roll on to the outside of the ankle) than an eversion injury (where you roll on to the inside of the ankle)

Management

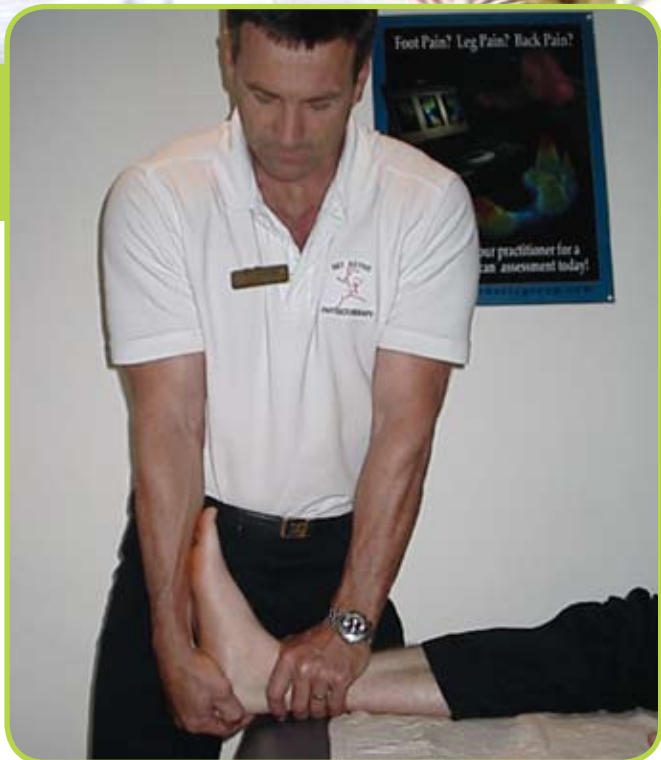As with all traumatic injuries it is essential the client is examined by a physiotherapist or sports physician as soon as possible. The medical professional will evaluate the extent of the injury and outline an approximate time line for rehabilitation, as well as excluding any more serious problems such as fractures and dislocations.

Once the ankle injury is diagnosed and other problems excluded, initial management will aim to reduce pain and swelling. This is best achieved with ice, elevation and compressive bandaging.

Pain-free ankle mobilisation exercises are commenced following the application of ice – these gentle range-of-motion exercises are performed for 5-10 minutes each hour with the ice/exercise cycle repeated as often as possible. Depending on the extent of the injury, the patient may need to be non-weight-bearing for the first 24 hours – after that it is important to commence partial and then full weight-bearing with normal gait to assist in the restoration of full pre-injury range of motion, and prevent long-term ankle stiffness.

A functional rehabilitation and strengthening programme is commenced as soon as symptoms allow but always under the direction and guidance of the treating physiotherapist. Common exercises used at this time include one-leg squats, balancing single leg with eyes initially open then closed, wobble boards and various balancing and catching drills.

Re-injury to the ankle is very common following return to activity –



it is essential that the joint returns to pre-injury range and stability prior to the return to full activity or sport. It is important to note that ankle strapping and bracing should be used during sport and training for a period of six to 12 months post injury. [fn](#)



Paul Wright B App Sc (Physio) is the director of Get Active Physiotherapy in Australia. He is a featured presenter at many national and international health and fitness conventions, including the past six FitPro Spring Conventions. Paul has a range of DVDs on injury prevention, training and rehabilitation which can be previewed and purchased at www.getactivephysio.com.au